ISSN (Print) 1226-1750
ISSN (Online) 2233-6656
Journal of Magnetics 22(3), 519-524 (2017) https://doi.org/10.4283/JMAG.2017.22.3.519

Modified Oblique Sagittal Magnetic Resonance Imaging of Rotator Cuff Tears: Comparison with Standard Oblique Sagittal Images

Myung-Sik Ju[1]*, Hae-Kag Lee[2], and Ham-Gyum Kim[3]

[1]*Department of Radiology, Soonchunhyang University Bucheon Hospital, Bucheon 14584, Korea*
[2]*Department of Computer Science and Engineering, Soonchunhyang University, Asan 31538, Korea*
[3]*Department of Radiological Technology, Ansan University, Ansan 15518, Korea*

(Received 13 July 2017, Received in final form 6 August 2017, Accepted 9 August 2017)

Rotator cuff disease occurs in adults is very common cause of shoulder pain causes is known as one of the. Combined oblique coronal and oblique sagittal standard magnetic resonance (MR) imaging is highly accurate for detecting full-thickness rotator cuff tears. However, the accuracy of standard MR imaging is lower for partial-thickness tears. Small rotator cuff tears can be obscured by partial volume effect if the imaging planes are not orthogonal to the surface of the cuff. Angling the oblique sagittal images perpendicular to the lateral 2 or 3 cm of the supraspinatus tendon would reduce the partial volume effect, and might make tears in this region more conspicuous. The purpose of our study was to compare the accuracy for diagnosing rotator cuff tears of oblique coronal images supplemented with standard oblique sagittal images versus thinner-section modified oblique sagittal fat suppressed fast spin-echo T2-weighted images. For full-thickness supraspinatus tendon tears, our study confirms that oblique coronal and standard oblique sagittal images are very accurate for diagnosing tears, and that supplementing oblique coronal images with thinner-section angled oblique sagittal images does not improve diagnostic accuracy for those few full-thickness tears that are missed on standard MR images. In conclusion, there was a slight improvement in accuracy for diagnosing rotator cuff tears, particularly partial-thickness tears, for the staff radiologist using the thinner-section angled oblique sagittal images.

Keywords : MRI, Rotator Cuff, Modified Oblique Sagittal Scan

1. Introduction

Rotator cuff disease is known to be one of the most common cause of shoulder pain in adults. However, oblique coronal and oblique sagittal tests, which are standard magnetic resonance (MR) scans, are not sufficient for partial thickness rotator cuff tears, except for full-thickness rotator cuff tears, It is difficult to distinguish correctly [1-4]. In the diagnosis of rotator cuff disease, MR examination has a large role and plays an important role in determining arthroscopic surgery. Partial rupture of rotator cuffs accounts for a considerable number of shoulder diseases, and the pain felt by the patient can be removed only after arthroscopic surgery. Most of the rotator cuff tear occurs in the anterior and lateral sides of the supraspinatus tendon and is not perpendicular to the standard oblique coronal images and oblique sagittal images in the anatomical structure. Partial rotation of the rotator cuff may result in a partial volume effect if the image plane is not perpendicular to the surface of the cuff [5]. If the angle of the sagittal scan is 2-3 cm at the side of the superficial tendon, the partial volume effect can be reduced and the lesion can be represented more accurately. In this study, slice thickness and slice gap were reduced because the emphasis was on image formation of the superficial tendon. This study was performed to evaluate the diagnosis of hypertrophic tendon rupture more accurately than the standard sagittal image by examining the thinner section modified oblique sagittal image in addition to the coronal scan image [6]. The purpose of this study was to compare the accuracy of the diagnosis of rotator cuff tear with standard images of the oblique coronal images and oblique sagittal images and thinner section modified oblique sagittal fat suppressed fast spin-echo T2-weighted images.

©The Korean Magnetics Society. All rights reserved.
*Corresponding author: Tel: +82-32-621-5857
Fax: +82-32-621-5857, e-mail: ju6947@schmc.ac.kr

© 2017 Journal of Magnetics

2. Subjects and Method

Patients who visited our clinic from September 2010 to January 2011 were oblique coronal, oblique sagittal scan and modified oblique sagittal fat suppressed fast spin-echo T2-weighted MR scan image. A 3.0 Tesla scanner (Signa 3.0T HDx, GE Healthcare, Milwaukee, WI) and a phased-array shoulder coil (USA Instruments, Inc.) were used. Patient posture was performed by external rotation of the humerus. An oblique coronal image was scanned perpendicular to the glenoid fossa in the transverse image and scanned with TR / TE [effective] 4000 msec / 55 msec. The oblique sagittal image was scanned horizontally to the glenoid fossa in the transverse image and scanned with TR / TE [effective] 4067 msec / 68 msec. (ETL) 11, field of view 16 cm, matrix 384 × 224, slice thickness 3 mm (with 0.3 mm inter-slice gap), oblique coronal and sagittal scan. The modified oblique sagittal image was based on the mid-glenoid fossa seen in the oblique coronal image, and from the side of the supraspinatus tendon 2 to 3 cm, the scan angle was formed (About 35° off vertical). TR / TE [effective] 6517 msec / 68 msec, ETL 11, 16 cm field of view, matrix 384 × 224, slice thickness 2 mm (with 0.2 mm inter-slice gap) and fat suppression technique. A total of 75 patients were enrolled. Twenty-four patients had complete rotator cuff tears and 25 patients had partial tears. All patients with rotator cuff tear were associated with superficial tendons, but a minority of patients with complete rotator cuff tears affected the infraspinatus tendon. Eighteen patients with complete rotator cuff tears were male and 6 were female and the average age was 53 years (range 37 to 74 years). Fifteen patients were males and 10 were females. The mean age was 42 years (range, 18-67 years). Twenty-six patients were found to have no abnormal findings. Sixteen of them were male, 10 were female and the average age was 40 years (16-66). The surgical diagnosis of these 26 patients was performed in 7 patients with shoulder involvement syndrome, 4 with multiple instability, 4 with ganglion cyst, 2 with superior labrum anterior to posterior (SLAP) rupture, 2 with Bankart tear, one was a two-piece rupture, and one was a subscapularis tendon rupture. Seventy-five MR images were randomly selected by combining the histories of radiologists and specialists. The oblique coronal and oblique sagittal scan images were evaluated first, followed by oblique coronal and modified oblique sagittal images. Scan images were evaluated. A total of 5 points were assessed for the presence of partial tear, complete tear, and partial or complete tear of the rotator cuff. The scores of rotator cuff tear were evaluated as definitely negative, probably negative, equivocal, probably positive, and definitely positive in the above three cases of rupture. A complete rupture of the rotator cuff appears as an extension of the high signal from the joint bony surface of the tendon. A partial tear of the rotator cuff appears as a high signal in the joint or bursa-associated tendon, but is not affected by the overall thickness of the tendon [5]. In addition, each reader was evaluated by two measures: torn (partial or full-thickness tear) or not. Surgical results were based on the gold standard. The receiver operating characteristic (ROC) curves-characteristic curves generalize the presence or absence of partial thickness tears, full-thickness tears, and rotator cuffs (partial- or full-thickness) tears.

3. Result

Table 1 shows partial rupture, Table 2 shows complete rupture, and Table 3 shows the number of patients at each stage of 5 points for rotator cuff (partial or complete) rupture. The ROC curve is shown in Fig. 2 and 3, and the values of the ROC curve are shown in Table 4. Reader 1 is a specialist in radiology and Reader 2 is a radiologist.

3.1. Partial thickness rotator cuff tears

Reader 2 showed statistically significant improvement in diagnostic accuracy in the oblique sagittal plane examination compared to the standard oblique sagittal plane examination in patients with partial rupture. The two

Table 1. Number of patients with MR score for diagnosing a partial thickness rotater cuff tear (PT: partial thickness rotater cuff tear, OC: oblique coronal, OS: oblique sagittal).

Reader 1-surgical findings		
MR score	OC-standard OS No partial tear/ partial tear	OC-modified OS No partial tear/ partial tear
definitely no FT	23/1	25/0
probably no FT	11/11	9/7
equivocal	6/4	5/14
probably FT	8/9	8/10
definite FT	2/0	3/4
Reader 2-surgical findings		
	OC-standard OS No partial tear/ partial tear	OC-modified OS No partial tear/ partial tear
definitely no FT	32/2	39/0
probably no FT	7/9	8/4
equivocal	8/2	2/3
probably FT	3/9	1/9
definite FT	0/3	0/9

Table 2. Number of patients with MR score for diagnosing a full-thickness rotater cuff tear (FT: full-thickness rotater cuff tear, OC: oblique coronal, OS: oblique sagittal).

Reader 1-surgical findings		
MR score	OC-standard OS No partial tear/ partial tear	OC-modified OS No partial tear/ partial tear
definitely no FT	28/0	36/0
probably no FT	13/0	9/1
equivocal	3/0	3/1
probably FT	6/3	3/2
definite FT	1/21	1/20
Reader 2-surgical findings		
	OC-standard OS No partial tear/ partial tear	OC-modified OS No partial tear/ partial tear
definitely no FT	36/0	46/0
probably no FT	9/0	4/0
equivocal	5/1	0/0
probably FT	7/3	0/1
definite FT	0/20	1/23

Table 3. Number of patients with MR score for diagnosing a rotater cuff (partial or full-thickness) tear (OC: oblique coronal, OS: oblique sagittal).

Reader 1-surgical findings		
MR score	OC-standard OS No partial tear/ partial tear	OC-modified OS No partial tear/ partial tear
definitely no FT	1/1	4/0
probably no FT	7/5	7/4
equivocal	6/2	3/2
probably FT	4/4	5/5
definite FT	8/37	7/3
Reader 2-surgical findings		
	OC-standard OS No partial tear/ partial tear	OC-modified OS No partial tear/ partial tear
definitely no FT	13/2	15/0
probably no FT	4/9	7/4
equivocal	4/2	2/3
probably FT	4/7	1/8
definite FT	1/29	1/34

ROC curve difference areas were 15 % (95 % confidence interval (CI) = 7-5 %). The number of probable or definitely evaluated partial rupture patients was 12 in the standard sagittal coronal plane and the oblique sagittal plane, but 18 in the sagittal plane of the deformed sagittal plane. The number of patients with no partial rupture estimated to be probably or definitely increased from 39 to 47. Reader 1 also improved the accuracy of the diagnosis in the oblique sagittal plane in patients with partial rupture, but it was not statistically satisfactory. Reader 1 increased the number of partially ruptured patients evaluated to probably or definitely from 9 to 14, but the number of patients without a partial rupture estimated to be probably or definitely was equal to 34.

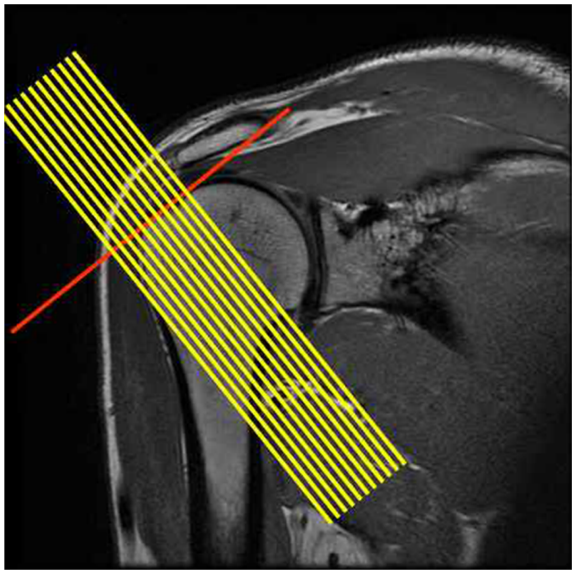

Fig. 1. (Color online) Oblique coronal fast spin-echo T2-weighted image (TR/TE, 6517 ms/68 ms) through the mid-glenoid fossa with modified oblique sagittal image locations oriented perpendicular to the down-sloping laterl rotater cuff tendon.

3.2. Full-thickness rotater cuff tears

We found that the difference in diagnostic ability was slightly reduced in patients with complete rupture, but the accuracy of the diagnosis was high in the standard method and the modified method. (Area under the ROC curves 0.974-0.996). The reason why there is little difference in the curves between the ROC curves of Reader 1 and 2 is that the number of probable tear patients was low in the standard method and the number of probably not patients in the deformation test method was small.

3.3. No tear versus partial or full-thickness tear

Reader 2 shows statistically that deformation test is more accurate than standard method in patients with partial or full-thickness tear. ROC curve (95 % CI: 4-6 %) with a 9 % difference in the area. The number of patients evaluated as probably or definitely increased from 36 to 42, and the number of patients evaluated as probably or

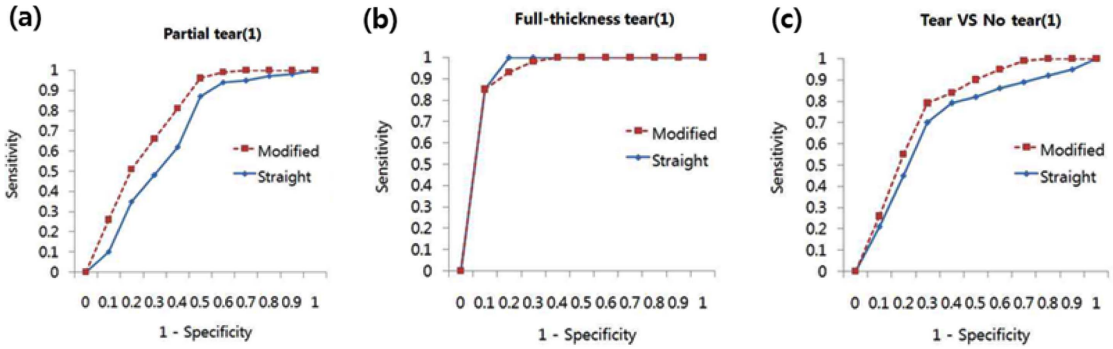

Fig. 2. (Color online) A-C Receiver operating characteristic curves for reader 1. Figure A is distinguishing patients with a partial-thickness rotater cuff tear from patients without a partial tear. Figure B is distinguishing patients with a full-thickness rotator cuff tear from patients without a full-thickness tear. Figure C is distinguishing patients with a rotator cuff partial or full-thickness tear from patients without a tear.

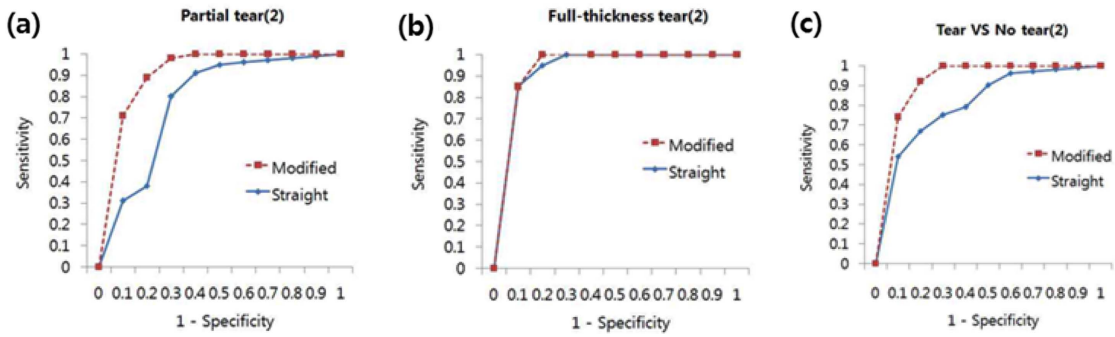

Fig. 3. (Color online) A-C Receiver operating characteristic curves for reader 2. Figure A is distinguishing patients with a partial-thickness rotator cuff tear from patients without a partial tear. Figure B is distinguishing patients with a full-thickness rotator cuff tear from patients without a full-thickness. Figure C A-C Receiver operating characteristic curves for reader 2.

Table 4. Area under the receiver operating characteristic curves (OC: oblique coronal, OS: oblique sagittal).

	OC-standard OS	OC-angled OS	Difference	95 % CI
Reader 1				
partial tear	0.6952	0.7812	–0.086	–0.187, 0.020
full-thickness tear	0.9816	0.9739	0.077	–0.007, 0.029
any tear	0.7245	0.779	–0.0545	–0.158, 0.040
Reader 2				
partial tear	0.8192	0.9692	–0.15	–0.248, –0.071
full-thickness tea	0.9959	0.9848	0.0061	–0.006, 0.025
any tear	0.8528	0.9466	–0.0938	–0.162, –0.041

definitely not increased from 17 to 22. Reader 1 had a tendency to improve diagnostic ability in patients with rotator cuff (partial or full-thickness) tears in the modified sagittal direction test, but this was also not a statistically acceptable value. In Reader 1, the number of patients evaluated as probably or definitely torn increased from 41 in the standard method to 43 in the modified method.

4. Discussion

Partial rupture of joints and bursitis the precise diagnosis of MR is based on the presence or absence of a clear description of the shape of the rotator cuff. The blurring of the cuff surface due to different signal intensities within the same voxel (partial volume effect) due to the oblique

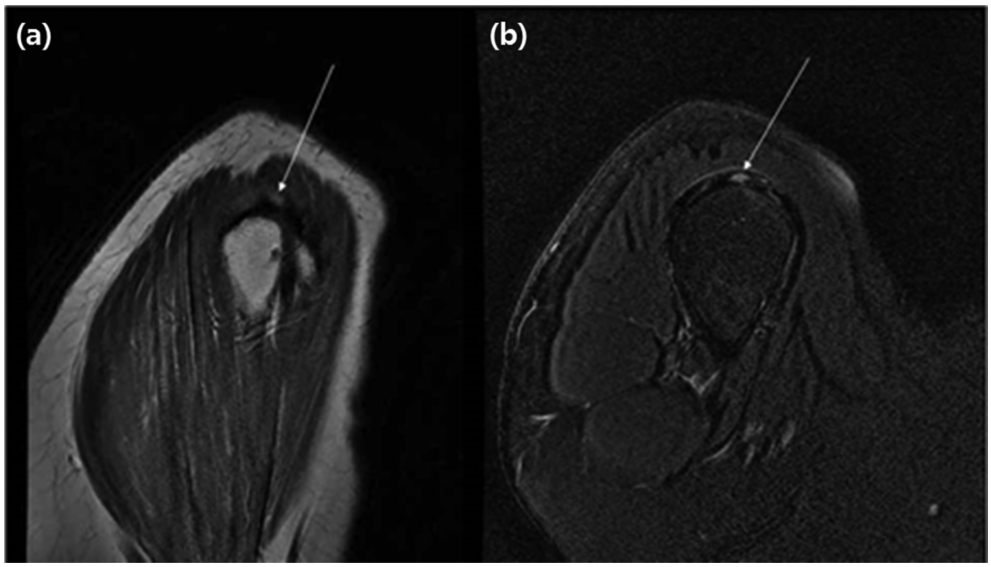

Fig. 4. A 55-year-old woman with an articular surface partial thickness rotater cuff tear. Figure A is T2 weight image and figure B is fat suppression T2 weight image.

anatomical structure is shown in Fig. 4 can be obtained [7]. The anterior and lateral tear of the superficial tendon is often seen [8], but the small tears in this region are more likely due to the partial volumetric effect of the standard oblique coronal and oblique sagittal scan is difficult. The improvement in the diagnostic accuracy of partial cuff tears MR imaging in this article may be due to the more detailed description of the rupture area, possibly minimizing the partial volumetric effect. Partial volume effect is a type of artifact arising from the margins of a piece, which can minimize artifacts by minimizing slice thickness. Another potential reason may be that the slice thickness and slice gap (3 mm skip 0.2 mm versus 4 mm skip 1 mm) were minimized in the sagittal plane scan method in the deformed sagittal plane. In this study, slices were thinned in the lateral direction about 3-4 cm in height of the superficial tendon, and sufficient images were obtained with only 10-12 deformed oblique sagittal scan. This image could reduce the partial volume effect because of the smaller voxel size and less unimaged tendon in the inter slice gap. The standard oblique sagittal image was scanned to see the entire rotator cuff tendon with a thickness of 3 mm (with a 0.3 mm interslice gap), and thus the time required to acquire the image was long. In this study, we could not be sure how much the oblique sagittal scan method had a significant impact on the accuracy of the diagnosis and how thinner sections could be examined. It is certain that the modified sagittal test should be performed in parallel with the standard four-sided coronal and oblique sagittal examinations. Standard oblique sagittal images that can be examined up to the medial side of the glenoid fossa are very helpful in predicting patients with spinoglenoid notch ganglion, asymmetry, and irreversible rotator cuff tear. In addition, if a cuff rupture is present, it may not be fully included in the oblique sagittal scan. In addition, if a cuff rupture is present, it may not be fully included in the oblique sagittal scan. For this reason, we decided to add fat-suppressed fast spin-echo T2-weighted deformed sagittal images [with standard oblique sagittal fast spin-echo T2-weighted images extending from the mid- Portion of the supra-spinatus tendon) to about 3 cm medial to the glenoid fossa]. In this study, we could not establish the usefulness of the sagittal images of the deformed sagittal images to adequately describe the entire other anatomical structures of the shoulder. This is because the sagittal images of the deformed sagittal are very suitable for describing partial tear of the rotator cuff but not for patients with degenerative tears. It is obvious that additional examination of the sagittal image in the deformed sagittal direction will help in the accurate diagnosis of the stage of the partial tear, and it is helpful to add this sequence to the younger and more active patients [9, 10]. In our study, we found that the accuracy of the diagnosis of rotator cuff tears was higher in patients with full-thickness supraspinatus tendon tears than in patients with standard sagittal and oblique sagittal images, and did not improve the accuracy of the diagnosis. Patients with partial rotator cuff tear were found to have improved diagnostic accuracy when tested with sagittal scan. In this study, we could show the improvement in the accuracy of the diagnosis in the sagittal images of the deformed sagittal, but this was possible because the

proportion of the patients who participated in this study was dominated by small cuff tears. The radiologist showed that the sagittal images of the deformed sagittal images had a greater improvement in the accuracy of the diagnosis than did the fellow. We did not know exactly why the radiologists who participated in the study were more accurate than the residents, but the sagittal images of the deformed sagittal images provided a more specific image plane to the radiologist who reads the shoulder MR images but it was very effective.

5. Conclusion

In conclusion, thinner-section angled oblique sagittal images in the diagnosis of rotator cervical cancers, especially in patients with partial-thickness tears, showed a slight improvement in radiologists. The sagittal images of the deformed sagittal images may have the effect of increasing the accuracy of the rotator cuff diagnosis by adding this sequence to patients with tears that are younger and cause movement.

Acknowledgments

Myung-Sik Ju and Hae-Kag Lee equally contributed to this work. They are co-first authors.

This work was supported in part by the Soonchunhyang university Research Fund.

References

[1] R. M. Patten, R. P. Spear, and M. L. Richardson, Invest. Radiol. **29**, 87 (1994).
[2] M. Rafii, H. Firooznia, O. Sherman, J. Minkoff, J. Weinreb C. Golimbu, R. Gidumal, R. Schinella, and K. Zaslav, Radiology **177**, 817 (1990).
[3] P. L. Robertson, M. E. Schweitzer, D. G. Mitchell, F. Schlesinger, R. E. Epstein, B. G. Frieman, and J. M. Fenlin, Radiology **194**, 831 (1995).
[4] A. H. Sonin, A. J. Peduto, S. W. Fitzgerald, C. M. Callahan, and M. E. Bresler, AJR Am. J. Roentgenol. **167**, 333 (1996).
[5] W. R. Reinus, K. L. Shady, S. A. Mirowitz, and W. G. Totty, AJR Am. J. Roentgenol. **164**, 1451 (1995).
[6] S. K. Goergen, W. G. Bradley, J. Liu, J. K. Tam, M. D. Dubin, P. J. Pema, L. M. Teresi, J. Jordan, and D. Morrison, J. Comput. Assist. Tomogr. **20**, 829 (1996).
[7] S. J. Erickson, Radiology **205**, 593 (1997).
[8] M. J. Tuite, J. R. Turnbull, and J. F. Orwin, Skeletal Radiology **27**, 237 (1998).
[9] S. S. Burkhart, Arthroscopy **10**, 4 (1994).
[10] S. J. Snyder, A. F. Pachelli, W. Del Pizzo, M. J. Friedman, R. D. Ferkel, and G. Pattee, Arthroscopy **7**, 1 (1991).